

UNIVERSIDADE LUSÓFONA
de Humanidades e Tecnologias
Humani nihil alienum

Low Frequency Noise and Health: A Wind Turbine Case (2007-2013)

Mariana Alves-Pereira, Ph.D.
Lusofona University, Lisbon, Portugal

Nuno A. A. Castelo Branco, M.D.
Principal Investigator, Vibroacoustic Disease

UTRECHT, The Netherlands 11 Oct 2013

eceo
escola de ciências económicas e das organizações

ESCOLA SUPERIOR DE SAÚDE RIBEIRO SANCHES
Instituto de Saúde e Ambiente

Low Frequency Noise Evaluation Problems

Noise is a Pressure Wave:
A time-varying force
impacting upon a surface.

Rudimentary and outdated
segmentation of the
acoustical spectrum.

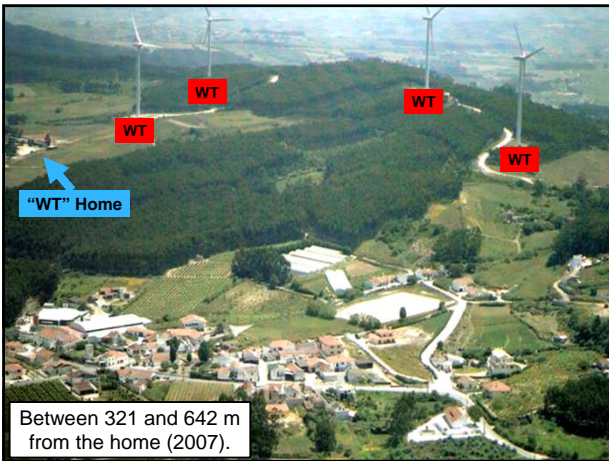
Gravity Waves Infrasound Audible Sounds (Limits of human hearing) Ultrasound

The dBA unit is inappropriate
for measuring LFN

Disclaimer

We:

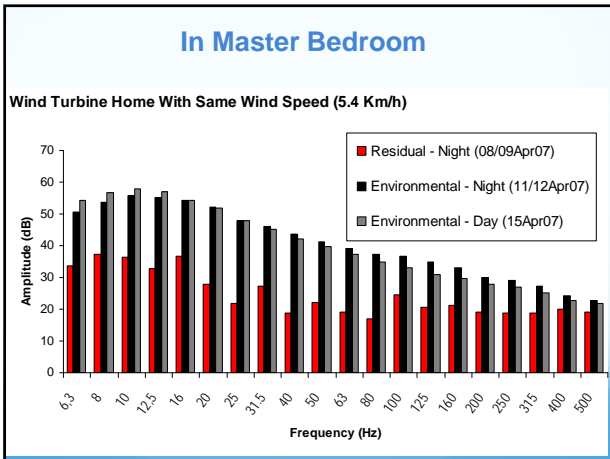
- Do not harbour anti-technology sentiments;
- Consider Wind Turbines as welcome additions to modern technological society;
- Have scrutinized data under one, and only one, agenda - pure scientific inquiry;
- Are not producing a report arguing against the implementation of Wind Turbines;
- Are not contractually (or otherwise) linked to the firm that conducted the acoustical measurements; and
- Have provided consulting activities to this family, of a purely academic and scientific nature, and hence pro bono.





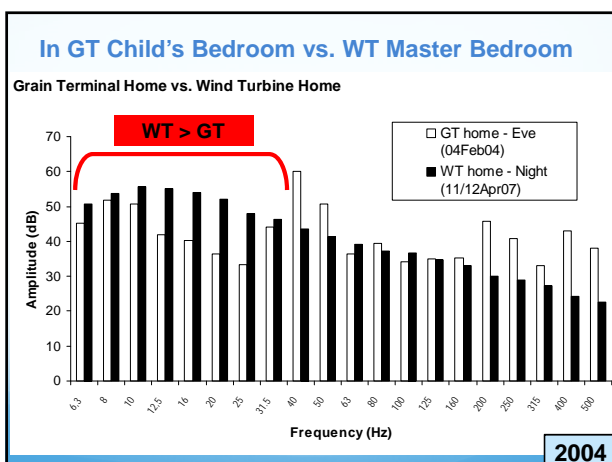
Infrasound & Low Frequency Noise
Technical Details of Measurements

- **dBLin**
- 1/3 octave bands
- **1-500 Hz** (herein reported: 6.3-500 Hz)
- 01dB Symphonie
- ½" microphone (GRAS, model 23606)
- **Continuous - Apr 5th-16th, 2007**
- 30-min periods
- **Wind Speed + Structural Vibrations**









Problems in the WT Home

- WT began operation in Nov 2006.
- Inability to obtain restful sleep; increased irritability.
- Dog, horse, and ant behaviour.
- Mar 2007: letter from school (12-yr-old):
"...It seems that [the child] has lost interest, makes a lesser effort, as if he were permanently tired".

Our team was contacted in March 2007, and the following complementary diagnostic tests were recommended:

- Echocardiograms, P300, PCO₂ respiratory drive.

Vibroacoustic Disease (VAD)

Clinical Stages

Mild 1-4 years of LFN exposure
 Slight mood swings, indigestion & heartburn, repeated mouth & throat infections, bronchitis.

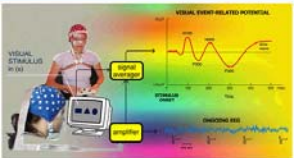
Moderate 4-10 years of LFN exposure
 Chest pain, back pain, fatigue, fungal & viral skin infections, allergies, blood in urine, inflammation of stomach lining.

Severe > 10 years of LFN exposure
 Psychiatric disturbances, headaches, hemorrhages of nasal & digestive mucosa, duodenal ulcers, spastic colitis, varicose veins & hemorrhoids, decreased vision, severe joint pain, severe muscular pain, neurological disturbances.

VAD Clinical Signs in the WT home


P300-Event-Related Potentials in Child

Jun 2007: **352 ms**
 Sep 2007-after 2 mo. holiday: **322 ms**
 (norm: **300 ms**)



Respiratory Drive

39-year-old father: **46%**
 42-year-old mother: **53%**
 (norm: **>60%**)





Echocardiography Score for Pericardial Thickening:

39-year-old father: **1**
 42-year-old mother: **1**
 12-year-old child: **1**

2007 Legal Proceedings

Standing Court Order


- WT No. 2, closest to home, at 322 m was ordered to be shut down.
- All other (3) WT were ordered to be shut down during the evening (8-11 pm) and night hours (11 pm – 7 am).
- Meanwhile, the installation of WT continued in the contiguous vicinity of the R family home.


Situation in 2010

Lusitanian Horses


- Mrs. R and the children have moved.
- The child has normal P300 values.
- Mr. R. must stay to care for thoroughbred Lusitanian horses.
- Mr. R's health is visible deteriorating, with increased cognitive impairment and severe noise intolerance.
- Between 2000 and 2006, 13 healthy thoroughbred Lusitanian horses were born and raised on Mr. R's property.
- All 4 horses raised after 2007 developed asymmetric equine flexural limb deformities (EFLD).
- All 4 were studied + 1 control.



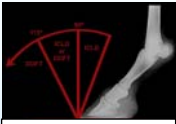
Equine Flexural Limb Deformities (EFLD)



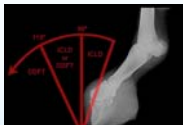
Espartaco – Case 4
Born: 02May09 and raised on R's Farm;
Father: Zircão;
Mother: Vassoura.



Engenheiro – Case 5
Born: 17May09 and raised on R's Farm;
Father: Zircão
Mother: Zizi





Normal right forelimb:
Hoof wall-to-floor angle is $>115^\circ$





EFLD left forelimb:
Hoof wall-to-floor angle is $<115^\circ$

Corrective Surgery: severing the accessory or check ligament.









Case 1 (Canela; Born: 26Feb07), Case 4 & Case 5:
Born and raised on Mr. R's farm.


Case 2 (Desplante; Born: 20Apr08):
Acquired at 15 days of age and raised on farm.

Case 3 – Control - (Dondoca; Born: 04Apr08):
Acquired at 14 months of age.


Response of Biological Tissue to LFN

In all cases (1,2,4 & 5), **blood vessel walls were abnormally thickened** due to the presence of collagen. No such images were seen in Case 3. Cells normally associated with inflammatory processes were absent from all images.

This unusual biological feature is the hallmark of LFN exposure.



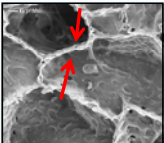
Blood Vessel Wall Thickening
in LFN-exposed Wistar rat.



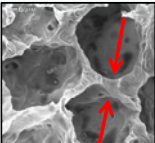
Blood Vessel Wall Thickening
in Vibroacoustic Disease Patient.

Response of Biological Tissue to LFN

Structural thickening due to abnormal growth of collagen in the absence of an inflammatory process.




Control



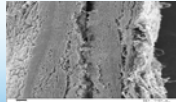
LFN-Exposed

Thickening of Alveolar Walls
(LFN-exposed Wistar rat).

Note: Scale of paired images is the same.



Control



VAD patient

Thickening of Pericardium
(VAD patient).

Today – 2013

Supreme Court Order on R. Family's Case:

- The remaining 3 WT must be removed.
- Monetary retribution to the R. Family was increased from the previous value stipulated by the lower court.

Meanwhile, Mr. R's health has visibly deteriorated further.

Master's Thesis – School of Veterinary Medicine, Technical University of Lisbon

“Acquired flexural deformity of the distal interphalangeal joint in foals” (2012), by Teresa Margarida Pereira Costa e Curto.






Thank you for your attention!

m.alvespereira@gmail.com

This is my thank you dance!